

Special cases

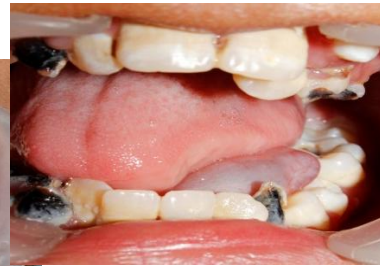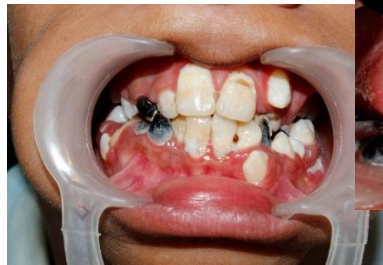RANULA :

Extra oral examination

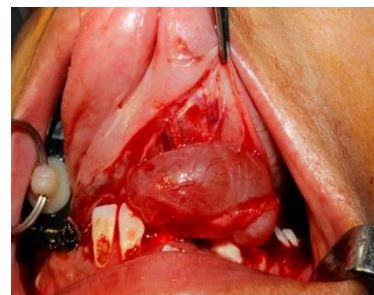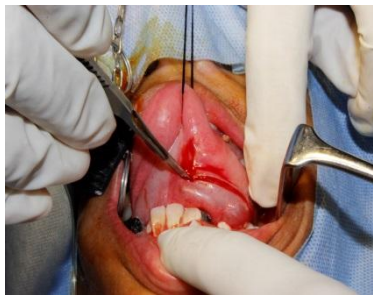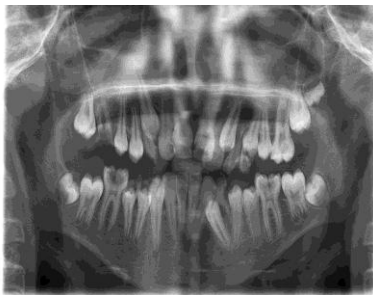Intra oral findings



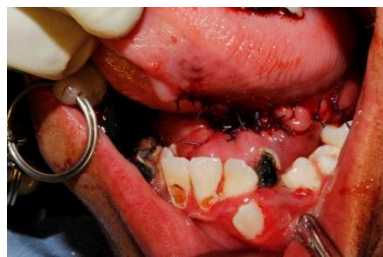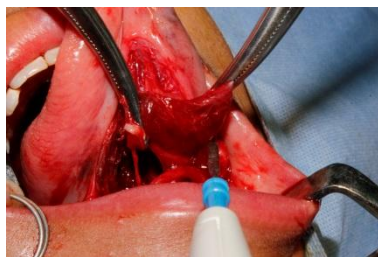OPG of the patient



Surgical Marsupialization Under General Anesthesia



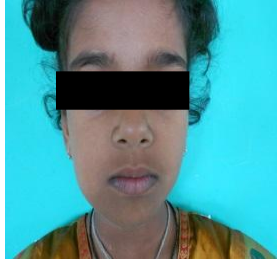Complete excision and sutures placed



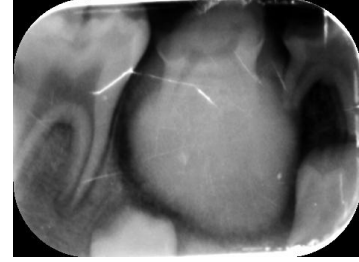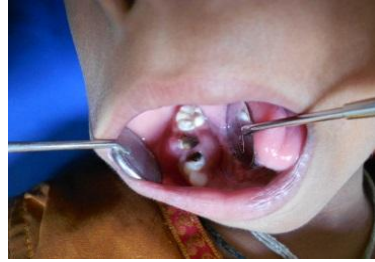CEMENTOBLASTOMA

Preoperative photographs

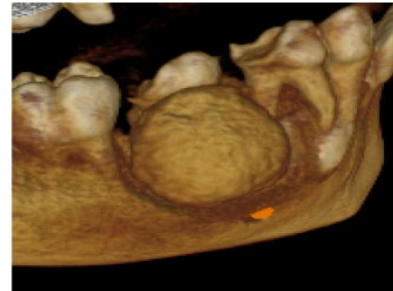
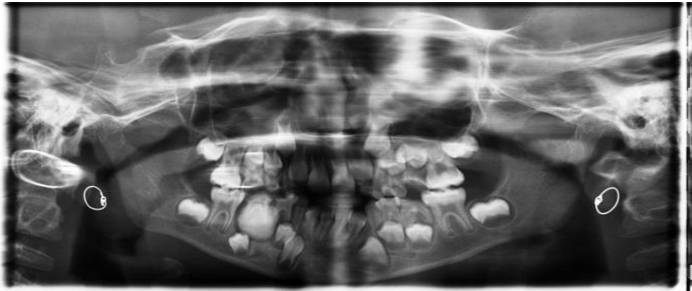IOPAR WRT 84 and 85



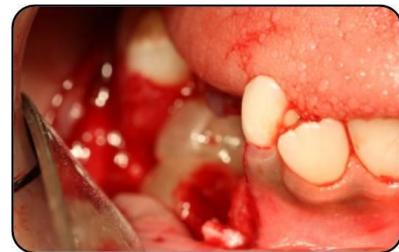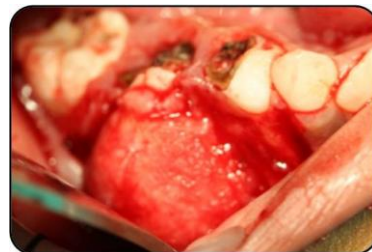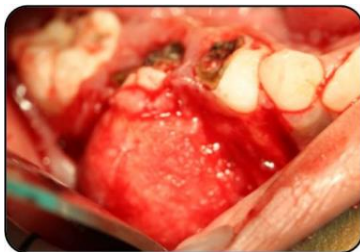OPG



CT scan

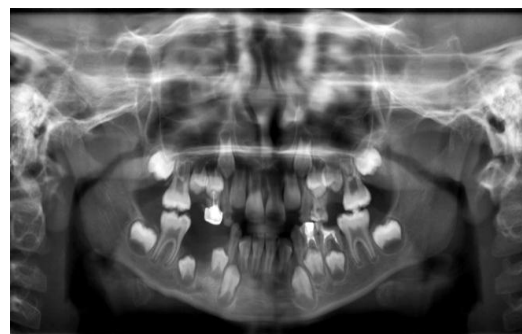
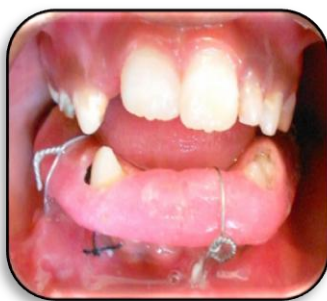
Surgical Excision Under General Anesthesia



Immediate Post Operative Splinting

6 Months Follow Up clinical and OPG

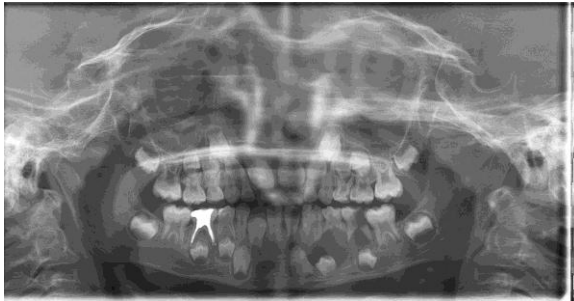

DENTIGEROUS CYST

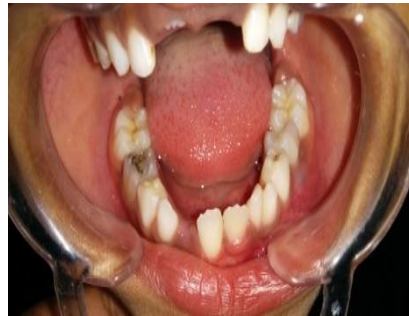Extra oral examination



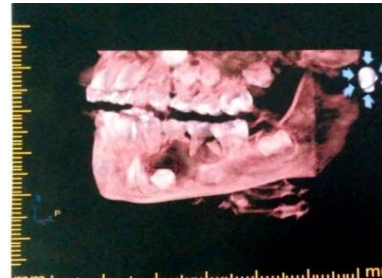
OPG



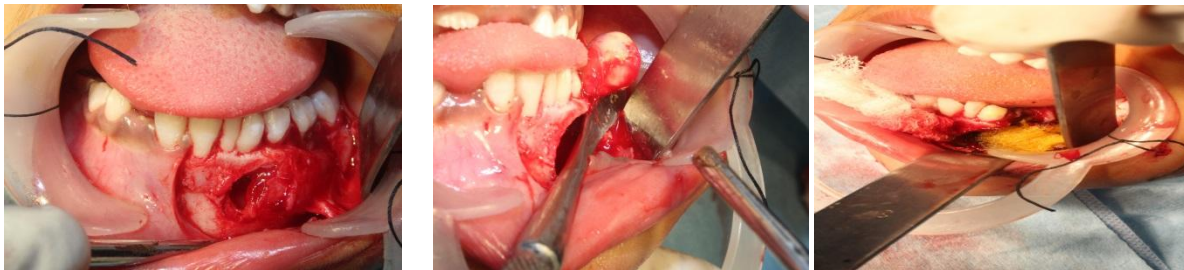
Intra oral findings



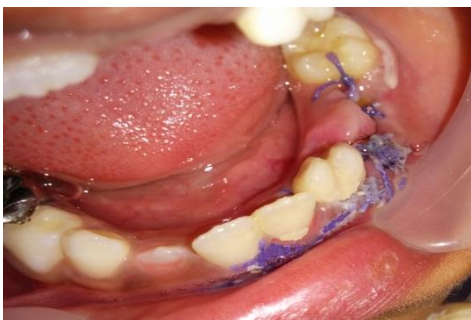CT Scan



Surgical Excision of Cyst Under General Anesthesia followed by placement of PRP



Suturing done following placement of PRP



3 month follow up clinical examination

